



NLR Skin Disease Games - Do-It-Yourself (DIY) version

Flashcards

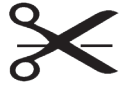- It is recommended to print on thick paper or cardboard.
- The front and back of each card are displayed on one page.
- Cut them out and glue them together.
- There are cutting lines printed on the pages. Follow these to ensure the correct sizes of the cards (154 x 111 mm).
- The blue square bleeds a bit over the cutting lines, to ensure no white lines appear on the side of the cards; i.e. you will need to cut a small line of blue off each card.

For questions contact: SkinApp@nlrinternational.org



EDCTP

The project leading to the development of this game is part of the EDCTP2 programme supported by the European Union.
Grant number: RIA2017NIM-1839-PEP4LEP

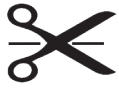

FRONT

Developed by NLR © 2019
www.nlrinternational.org

NLR Skin Disease Games

Flashcards



BACK

Copyright on one of the photos in the game? Please let us know via SkinApp@nlrinternational.org

NLR Skin Disease Games

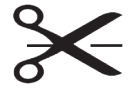These flashcards are part of the NLR Skin Games. The NLR Skin Games were originally developed under the PEP4LEP project, funded by the EDCTP and LRI.

How to play

1. Read the case
2. Guess the diagnosis
3. Turn card to see if you were right

The project leading to the development of this game is part of the EDCTP2 programme supported by the European Union.
Grant number: 642027/MA-1320-EP4LEP
Grant number: 642027/MA-1320-EP4LEP

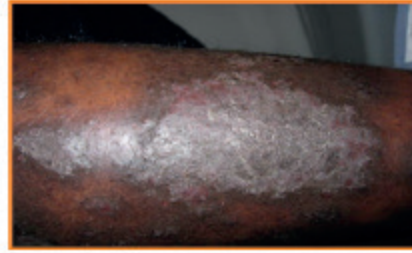Version 4, 2020



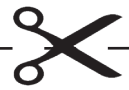FRONT

Case 1

64-year-old with scales



Thick, white sharply defined scaly plaques are present, especially on the elbows and knees. On the scalp, diffuse scaling and mildly infiltrated plaques are seen. Some nails are affected. In the past, the patient experienced arthritis.



BACK

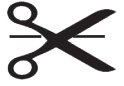Case 1



Psoriasis



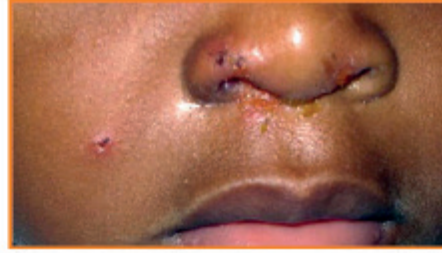Developed by NLR © 2019
www.nlrinternational.org



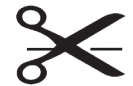FRONT

Case 2

4-year-old with crusts



Since 1 week yellow crusts, pustules and small wounds which look like open blisters are seen around the nose. Two classmates are experiencing the same symptoms.



BACK

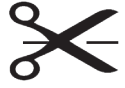Case 2



Impetigo



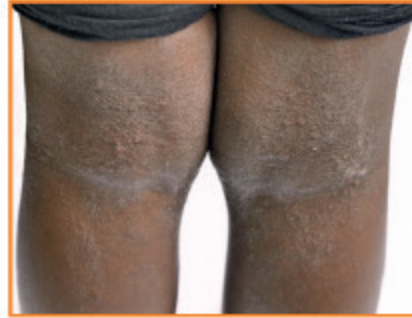Developed by NLR © 2019
www.nlrinternational.org



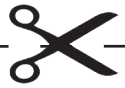FRONT

Case 3

8-year-old with itchiness



Dry skin, scaling, some papules (small bumps), lichenification (thick/leathery skin) and some scratch marks are seen. Affected areas are especially the elbow & knee folds.



BACK

Case 3



Atopic eczema



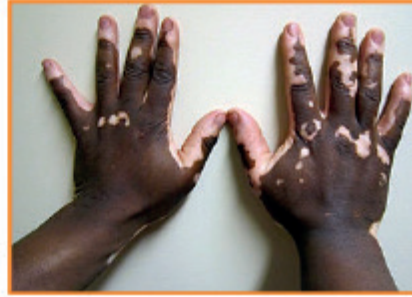Developed by NLR © 2019
www.nlrinternational.org



FRONT

Case 4

34-year-old with white macules



White macules (circumscribed colour change) are visible since many years. Depigmentation started around the mouth during childhood. It now also affects the hands. Affected areas are not painful or itchy and the sensation is normal.



BACK

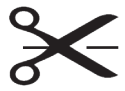Case 4



Vitiligo



Developed by NLR © 2019
www.nlrinternational.org

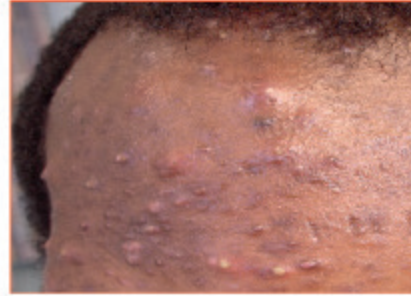

FRONT

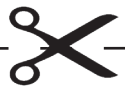

Case 5

16-year-old with pimples



Parts of the back and face are covered with the condition. An oily skin is seen including pustules, papules (small bumps) and comedones (white/black heads). Some parts of the affected skin show redness and scars.



BACK

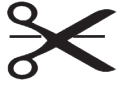Case 5



Acne



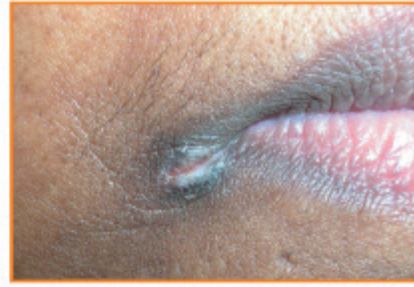Developed by NLR © 2019
www.nlrinternational.org



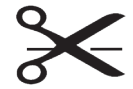FRONT

Case 6

34-year-old with cracks



Cracks are seen in the corners of the mouth. During consultation, the patient frequently licks his lips.



BACK

Case 6



Angular cheilitis



Developed by NLR © 2019
www.nlrinternational.org

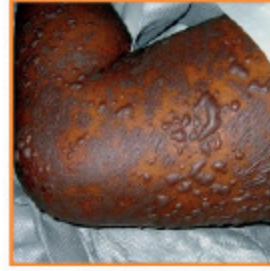

FRONT


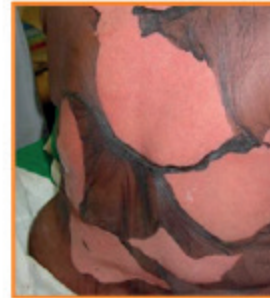
Case 7

29-year-old with blisters



Blisters cover a large part of the body surface as well as the mucous membranes (mouth, genitals). Some blisters are ruptured. The condition is extremely painful. It started recently, after taking new medication.



BACK

Case 7



Blistering disease

Refer directly to avoid death: this is an emergency!

Stop current medication



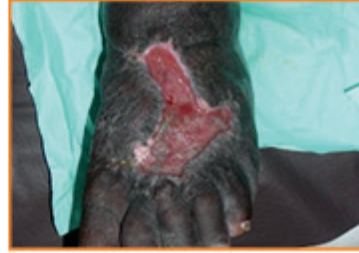Developed by NLR © 2019
www.nlrinternational.org



FRONT

Case 8

24-year-old with an ulcer



It started with a large painless swelling (nodule) under the skin, which has now become an ulcer. The ulcer is not painful and has been there for a few months.



BACK

Case 8

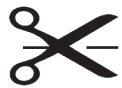

Buruli ulcer

Refer for treatment to avoid disability/disfigurement



Developed by NLR © 2019
www.nlrinternational.org

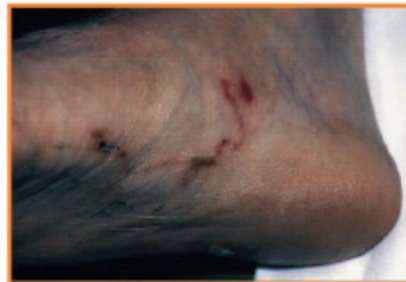

FRONT



Case 9

52-year-old with an itchy 'trail'



A winding trail/thread like lesion is located at his leg. The lesions is a little red. The lesion moves a few centimeters per day. The skin is locally swollen and very itchy. Scratch marks are observed.



BACK



Case 9

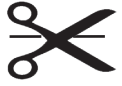

Creeping eruption (cutaneous larva migrans, CLM)

Caused by hookworm



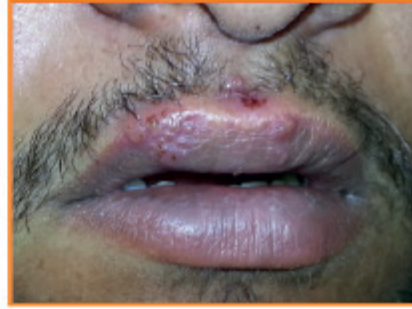Developed by NLR © 2019
www.nlrinternational.org



FRONT

Case 10

24-year-old with vesicles



Small grouped vesicles (blisters) are seen around the upper lip. Some vesicles are ruptured. A few months ago, the same symptoms were experienced.



BACK

Case 10



Herpes simplex



Developed by NLR © 2019
www.nlrinternational.org

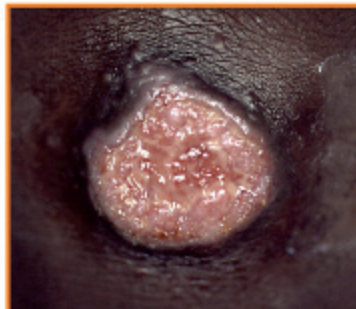

FRONT

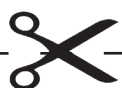

Case 11

7-year-old with an ulcer in the face



The girl was bitten by sand flies. After a few days, a painless nodule appeared with some redness. This turned into an ulcer.



BACK

Case 11



Cutaneous leishmaniasis

Refer for treatment to avoid disability/disfigurement



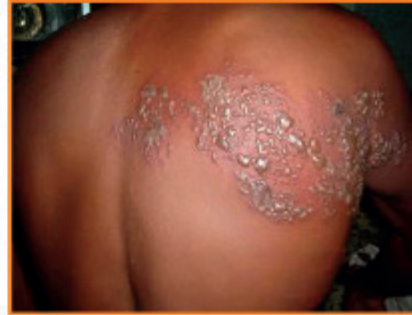Developed by NLR © 2019
www.nlrinternational.org



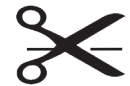FRONT

Case 12

55-year-old with painful vesicles



The patient experiences severe pain. Vesicles and crusts are seen on the right-hand side of the body (it does not cross the midline of the body).



BACK

Case 12



Herpes zoster



Developed by NLR © 2019
www.nlrinternational.org

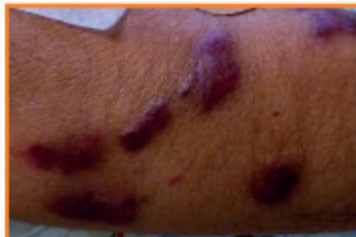

FRONT

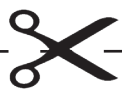
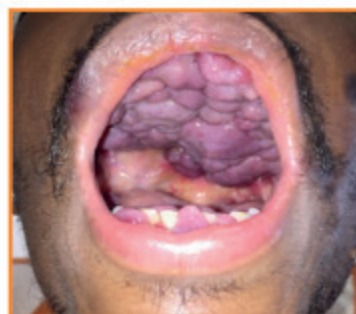
Case 13

40-year-old man with purple nodules



Red-purple plaques and nodules (large bumps) on the back and on the palate in the mouth are seen. The lesions feel hard when touching it. There are also swollen lymph nodes.



BACK

Case 13



Kaposi's sarcoma

Refer for treatment: this is cancer
Usually because of HIV/AIDS



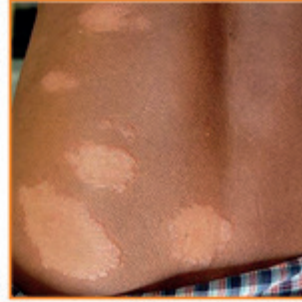Developed by NLR © 2019
www.nlrinternational.org



FRONT

Case 14

45-year-old with pale lesions



Some lighter coloured patches are seen on the back of a patient. The pink-whitish patches feel numb (loss of sensitivity). There is no itching.



BACK

Case 14

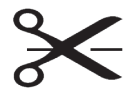

Leprosy

Refer for treatment to avoid disability/disfigurement



Developed by NLR © 2019
www.nlrinternational.org



FRONT

Case 15

58-year-old with a swollen leg



The edema is one-sided. In the beginning the swelling became less, but now it is continuously swollen. The skin is thickened and feels hard. Enlarged lymph nodes are present in the groin area.



BACK

Case 15



Lymphatic filariasis (LF)

Refer for treatment to avoid disability/disfigurement



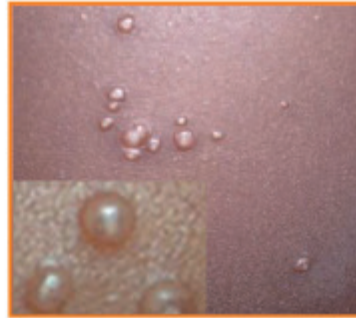
Developed by NLR © 2019
www.nlrinternational.org



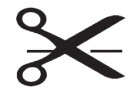FRONT

Case 16

7-year-old with small papules



The papules (small bumps) are shiny with a central dimple. One ruptured and contained a cheesy content. Some of the lesions are itchy.



BACK

Case 16



Molluscum contagiosum (water warts)



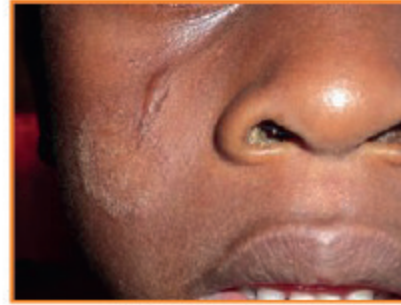Developed by NLR © 2019
www.nlrinternational.org



FRONT

Case 17

11-year-old with round lesions



Round skin lesions with a raised border are seen on the cheek. The centre of the lesions are lighter than the natural skin colour. Some scaling is seen. The spots are itchy. Sensitivity is normal.



BACK

Case 17



Tinea corporis
(ringworm)



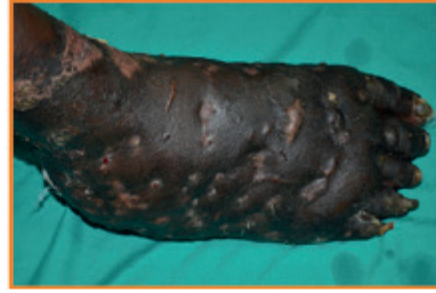Developed by NLR © 2019
www.nlrinternational.org



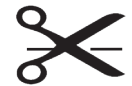FRONT

Case 18

28-year-old with a swollen foot



Edema, nodules (large bumps) and fistulas producing a yellow discharge (pus) are seen. Only the right foot is affected. It took a few years to get to this point. The patient walks barefoot.



BACK

Case 18



Mycetoma

Refer for treatment to avoid disability/disfigurement



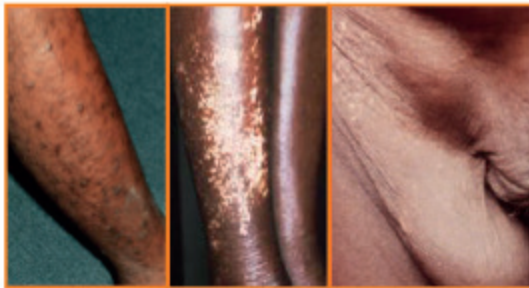Developed by NLR © 2019
www.nlrinternational.org



FRONT

Case 19

64-year-old with itchy dry legs



The skin is dry and thickened/leathery (lichenification) on various locations. It is very itchy, scratch marks are present. There are white spots and dark papules (small bumps) on the legs. There is a prominent hanging lump in the groin. In the same village a number of people are blind.



BACK

Case 19



Onchocerciasis (river blindness)

Refer for treatment to avoid disability/disfigurement



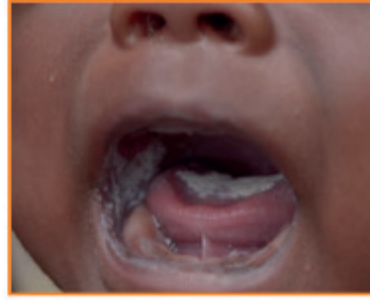Developed by NLR © 2019
www.nlrinternational.org



FRONT

Case 20

A baby with a white tongue



White plaques and superficial erosion at the tongue and palate are seen.



BACK

Case 20



Oral candidiasis
(oral thrush)



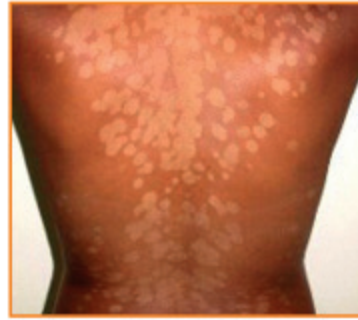Developed by NLR © 2019
www.nlrinternational.org



FRONT

Case 21

20-year-old with light spots on his back



Small (<1cm) hypopigmented spots and fine scaling on the back are present. Sensitivity is normal. There is no severe itchiness and no pain.



BACK

Case 21



Pityriasis versicolor



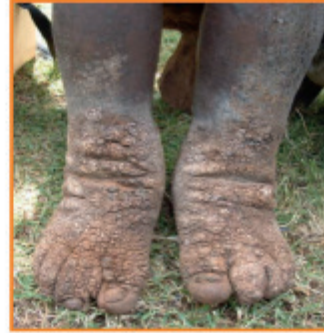Developed by NLR © 2019
www.nlrinternational.org



FRONT

Case 22

42-year-old with swollen feet



Painful edema is seen on both lower legs and feet. First the swelling went away, but it came back again. Now it is continuously swollen. There are some nodules (large bumps). The skin feels thick/leathery (lichenification).



BACK

Case 22



Podoconiosis (nonfilarial elephantiasis)

Refer for treatment to avoid disability/disfigurement



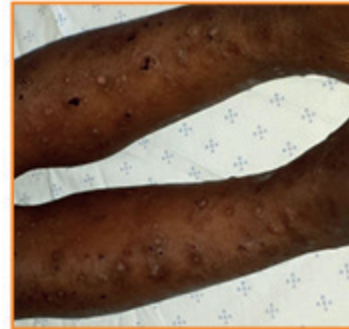Developed by NLR © 2019
www.nlrinternational.org



FRONT

Case 23

33-year-old with itchy papules



Scratch marks and early signs of scarring are visible. The itchiness is very annoying, especially at night. The papules (small bumps) are existing for about a month. The lesions are symmetrically located over the entire body.



BACK

Case 23



Pruritic papular eruption

(insect bite reaction)

In adults a sign of HIV/AIDS (refer)



Developed by NLR © 2019
www.nlrinternational.org


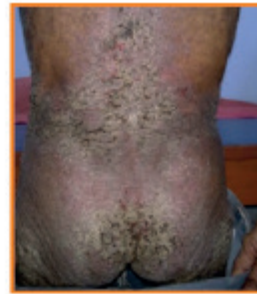
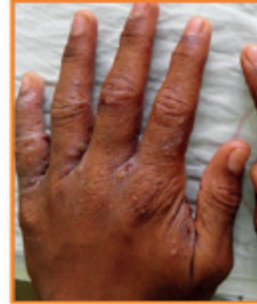FRONT

Case 24

27-year-old man with severe itchiness at night

Small bumps (papules), pustels and vesicels are seen between the fingers, at the wrists and ankles. All lesions are small. Some thin, irregular burrow tracks are visible. It itches at night and scratch marks are visible. His wife has the same symptoms for a longer period, also including crusts on her backside.



BACK

Case 24



Scabies



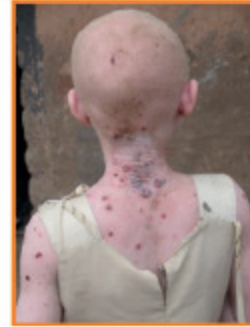Developed by NLR © 2019
www.nlrinternational.org



FRONT

Case 25

9-year-old with white skin



The girl's skin and hair have been white since she was born. Some dark and red spots are visible, like freckles and moles. Her skin is sensitive to the sun. She suffers from eye/vision problems.



BACK

Case 25



Albinism

Congenital (inborn) condition



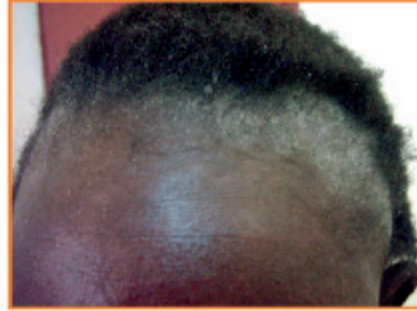Developed by NLR © 2019
www.nlrinternational.org



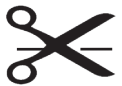FRONT

Case 26

27-year-old with scales



Greasy scales with some redness are visible on the scalp, forehead, and both sides of nose. The affected areas are sometimes itchy.



BACK

Case 26



Seborrhoeic eczema

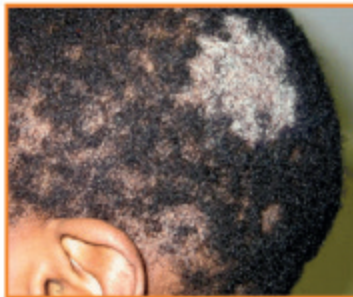

Developed by NLR © 2019
www.nlrinternational.org



Case 27

9-year-old with hair problems



Round lesions with hair loss are visible at the scalp. Some white scaling and small crusts are seen. He has enlarged lymph nodes in his neck. His sister has the same lesions. The boy regularly helps his father on a farm.



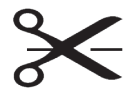Case 27



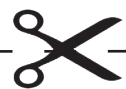Tinea capitis



Developed by NLR © 2019
www.nlrinternational.org



FRONT



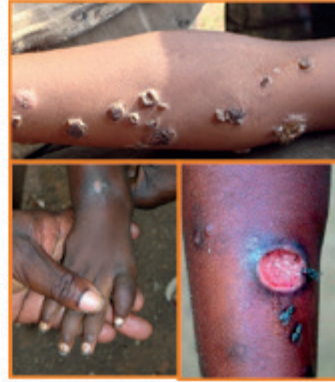BACK



FRONT

Case 28

7-year-old with ulcerations



The first lesion started as a wart-like nodule (large bump) and looked like a raspberry. New nodules appeared, some broke into a wet, pink, easily bleeding ulcer. The ulcers are not painful. The fingers are swollen and sensitive.



BACK

Case 28



Yaws

Refer for treatment to avoid disability/disfigurement



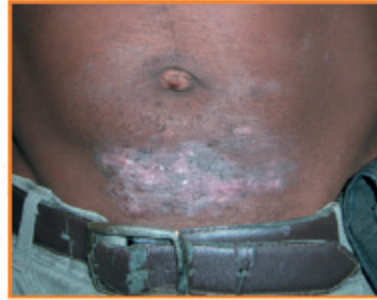Developed by NLR © 2019
www.nlrinternational.org



FRONT

Case 29

A 17-year-old with itchy skin irritation



Lichenification (thick/leathery skin) and scaling is only seen on the lower abdomen. The lesion is itchy, red and moist (wet). It is only seen on his lower abdomen. He is wearing a belt which contains the metal nickel.



BACK

Case 29



Contact eczema (due to nickel)



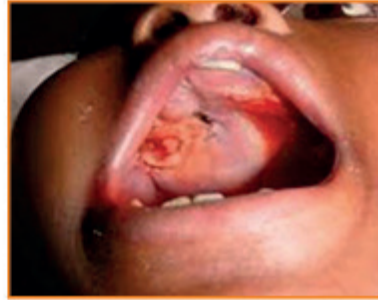Developed by NLR © 2019
www.nlrinternational.org



FRONT

Case 30

A 3-year old with a painful lesion in her mouth



A 3-year old malnourished girl is seen with a painful lesion (sore) on her palate of her mouth and swollen gums that bleed when touched. Her breath smells unpleasant. Within a few days, the lesion develops into an ulcer, and afterwards into necrosis and scarring which is destroying the soft tissues and bones of the mouth. She has a fever.



BACK

Case 30



Noma

Refer directly to avoid death or further disfigurement!
This is an emergency



Developed by NLR © 2019
www.nlrinternational.org